

Resistant Tuberculosis in HIV-Positive Patients: A Growing Public Health Threat

Safae Elfirdaous Fari¹, Maamar Mouna^{1, 2}, Khibri Haja^{1, 2}, Nisserine Jait¹, Youssra Moussadik¹, Thameen Jaradat³, Wafae Ammouri^{1, 2}, Naima Moutassim^{1, 2}, Hicham Harmouche^{1, 2}, Zoubida Mezalek Tazi^{1, 2}, Mohamed Adnoui^{1, 2}

¹Department of Internal Medicine Avicenne, University Hospital, Rabat, Morocco

²Faculty of Medicine and Pharmacy, University Hospital, Rabat, Morocco

³Department of Neurosurgery, Avicenne University Hospital, Rabat, Morocco

Email address:

Safaelfirdaousfari@gmail.com (Safae Elfirdaous Fari), mounaennibi@yahoo.com (Maamar Mouna),

hajar.khibri@gmail.com (Khibri Haja), jaradat.thameen.ps@gmail.com (Nisserine Jait),

yousramoussadik6@gmail.com (Youssra Moussadik), jaitnissrine3@gmail.com (Thameen Jaradat),

wafaammouri@hotmail.com (Wafae Ammouri), hharmouche@yahoo.fr (Hicham Harmouche),

n.moutassim@hotmail.com (Naima Moutassim), z.tazimezalek@gmail.com (Zoubida Mezalek Tazi),

adnaouim@yahoo.fr (Mohamed Adnoui)

To cite this article:

Safae Elfirdaous Fari, Maamar Mouna, Khibri Hajar, Nisserine Jait, Youssra Moussadik, Thameen Jaradat, Wafae Ammouri, Naima Moutassim, Hicham Harmouche, Zoubida Mzalek Tazi, Mohamed Adnoui. Resistant Tuberculosis in HIV-Positive Patients: A Growing Public Health Threat. *American Journal of Internal Medicine*. Vol. 11, No. 3, 2023, pp. 55-59. doi: 10.11648/j.ajim.20231103.15

Received: April 17, 2023; **Accepted:** May 19, 2023; **Published:** May 31, 2023

Abstract: *Introduction:* Tuberculosis (TB) is a pathology considered one of the main causes of death by single infectious agent, ranking just after HIV / AIDS. Indeed, its emergence and the difficulty of its treatment, especially in the resistant form, in patients with co-infection with other diseases immunodéprimante as HIV. *Observation 1:* 31 years old presented with febrile headaches complicated by epileptic seizures. The MRI scan showed 3 cockeyed and multilocular lesions suggesting neuromeningeal tuberculosis. HIV serology came back positive and during the first line treatment he relapsed and the resistance test was positive. *Observation 2:* 45 progressive alteration of the state associated with signs of tuberculosis impregnation and a meningeal syndrome. BK in the CSF and in the sputum was positive and brain imaging allowed us to retain the diagnosis of a neuromeningeal tuberculosis. The patient was put on anti-bacillary ERIP k4 and a corticotherapy. The workup for co-infection was able to establish an HIV infection. After 3 weeks of anti-bacillary treatment, the patient had a bad evolution and the search for resistance came back positive. *Observation 3:* 25 years old, pulmonary tuberculosis manifested by a hemoptysis of small abundance associated with a deep alteration of the general state, 3 BK positive sputum, as well as the image of a tuberculous cavern on the thoracic CT. Bad evolution after 2 months of treatment of first worsening of symptoms neuro and systemic involvement the search for resistance came back positive. *Discussion:* Drug-resistant tuberculosis is a major global public health challenge. In this article, we present three cases of drug-resistant TB in HIV-coinfected patients, highlighting the emergence and increasing prevalence of multidrug-resistant TB (MDR-TB) strains worldwide. In order to control the spread of this dreaded disease, it is essential to improve treatment regimens, promote vaccination, educate affected patients, and promote adherence to treatment. *conclusion:* Diagnosis of drug-resistant tuberculosis should be prompt and considered if there is a delay or lack of improvement with conventional tuberculosis treatment.

Keywords: Tuberculosis, Co-infection, HIV, Drug Resistance, Mutations, Susceptibility, New Treatment Regimens, Prevention

1. Introduction

Tuberculosis is a serious disease, second only to HIV/AIDS as a leading cause of death from a single infectious agent. The treatment of TB, especially in cases of drug resistance, is complex. Patients co-infected with HIV or with diabetes are particularly vulnerable. The disease is a major global public health challenge, especially for young people from low socioeconomic backgrounds.

According to the WHO Global TB Report 2022, the number of new TB cases increased by 4.5% in 2021, affecting an estimated 10.6 million people. Deaths from TB reached 1.6 million, including 187,000 among HIV-positive people. TB drug resistance also increased by 3%, with 450,000 new cases of rifampicin resistance recorded. The COVID-19 pandemic has disrupted TB services, and conflict has exacerbated the situation in some areas.

This article presents three cases of resistant tuberculosis in HIV-positive patients hospitalized and followed at the clinical department of internal medicine-haematology of the CHU Avicenne in Rabat. These cases highlight the challenges we face in the fight against drug-resistant tuberculosis and underscore the importance of effective prevention and treatment strategies to curb the spread of this disease. [1, 2].

2. Observation 1

A 31-year-old female patient, 2 months after vaginal delivery, presented with headache followed by fever and abrupt seizures. Initial clinical examinations did not reveal any abnormality. Biological findings showed a significant inflammatory syndrome with anemia and lymphopenia. A brain MRI revealed three multilocular cocardial lesions, suggesting neuromeningeal tuberculosis. During the etiological workup, a retroviral HIV infection was triggered. The patient was treated with a standard first-line antibacillary regimen (ERIP K4: soniazide, rifampicin, pyrazinamide, and ethambutol), corticosteroid, and curative Bactrim to also cover cerebral toxoplasmosis due to immunosuppression. In addition, she received Depakine taking into account possible interactions especially with riphimicne considered as a potent enzyme inducer, which resulted in a clear initial improvement.

One month after the start of anti-tuberculosis treatment, in order to prevent an immune restoration reaction, antiretroviral treatment with dolutegravir, which crosses the blood-brain barrier well, was initiated. However, after one month, the patient developed new seizures, headache, and febrile confusion. A follow-up MRI showed an increase in the size of some parenchymal lesions, and a lumbar puncture confirmed the persistence of neuromeningeal tuberculosis. Genetic analysis of antibacillary resistance in cerebrospinal fluid revealed resistance to isoniazid. The patient was treated with second-line antibacillaries, including bedaquiline, which ultimately improved her condition.

She is currently being followed in our center and attends

regular consultations.

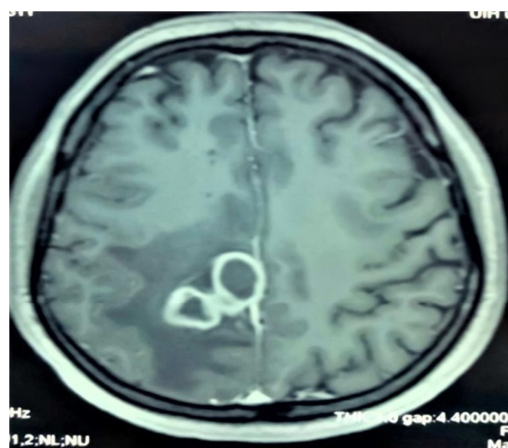


Figure 1. MRI brain tuberculosis cocardial image.

3. Observation 2

A 45-year-old patient accompanied her husband with pulmonary tuberculosis until his death a few months earlier. Her husband had been a carrier of the immunodeficiency virus years before, but he had chosen not to inform his partner of his diagnosis until some months before. Three months after her death, the patient began to progressively present with a meningeal syndrome, accompanied by signs suggestive of tuberculosis. Tests confirmed the diagnosis of neuromeningeal tuberculosis with the detection of liquid Koch's bacilli in cerebrospinal fluid and sputum, as well as on brain imaging.

She was treated with antibacillaries (ERIP K4) and corticosteroid therapy. However, after three weeks of treatment, the patient still had fever and meningeal stiffness, with no improvement. A new brain MRI showed no new abnormalities, but resistance tests revealed high resistance to all first- and second-line drugs. The patient was then placed on a regimen of third-line antibiotics, with a gradual introduction, and antiretroviral therapy was initiated with a double dose of Dolutegravir plus AZT. Unfortunately, the patient died rapidly, within two days of the diagnosis of her resistant form of the disease.

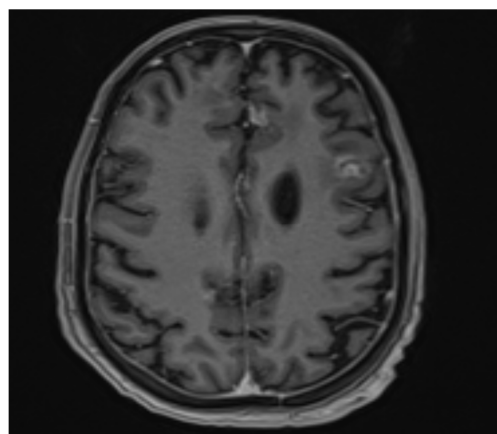


Figure 2. Image of cerebral tuberculosis MRI.

4. Observation 3

The third patient, aged 25 years, was initially admitted for mild hemoptysis associated with severe general condition. Three sputum examinations were performed, all positive for Koch's bacilli, and a chest CT scan showed a tuberculous cavern. The diagnosis of pulmonary tuberculosis was made and the patient was put on first-line anti-bacillary therapy (ERIP K4). However, the evolution was marked by the appearance of a neurological symptomatology including a pyramidal syndrome, a cerebellar syndrome and oculomotor paralysis of the VI and VII nerves. Genexpert study revealed multifocal pulmonary, urinary and neuromeningeal tuberculosis resistant to rifampicin and isoniazid. The patient is currently treated with second-line antibacillary drugs and for HIV treatment the patient is on dolutegravir with good progression.

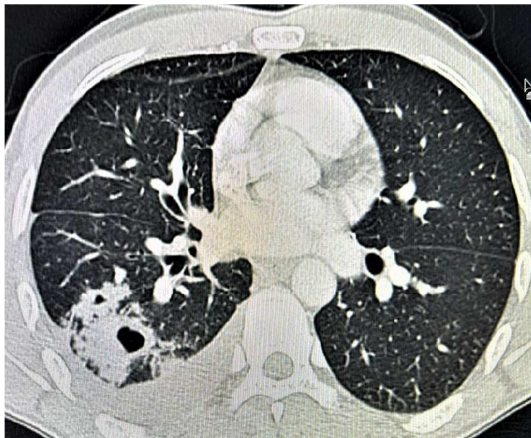


Figure 3. Image of pulmonary tuberculosis on CT scan.

5. Discussion

Resistant tuberculosis (DR-TB) is a form of tuberculosis that is resistant to at least two of the first-line drugs used to treat the disease. DR-TB strains arise as a result of spontaneous mutations or mutations induced by inappropriate anti-TB therapy. Germs that undergo a mutation that confers resistance temporarily lose some of their virulence, but this can be restored by new mutations. In practice, resistant mycobacteria can be assumed to be at least as virulent as susceptible mycobacteria, and the acquisition of resistance is not accompanied by a lasting loss of virulence [3]. The number of DR-TB cases appears to be gradually increasing in all regions of the world. The proportion of DR-TB cases in the total TB caseload varies by region, with the highest proportions occurring in Eastern Europe, Russia, Central Asia, India, and parts of Africa. In many parts of the world, the rate of drug resistance is unknown because of the lack of facilities to determine the susceptibility of the strains present to anti-tuberculosis drugs. The total number of multidrug-resistant cases and the proportion by region is therefore probably underestimated [4]. Poorly designed treatment regimens, inadequate patient compliance, or association with an immutable disease such as HIV may promote the

development of resistant forms of tuberculosis.

Multidrug-resistant tuberculosis (DR-TB) occurs when mutational selection of *Mtb* occurs during first-line anti-tuberculosis treatment, leading to resistance to rifampicin and isoniazid. Approximately 10% of patients also develop resistance to fluoroquinolones and second-line injectable drugs, leading to extensively drug-resistant tuberculosis (XDR-TB) following inappropriate treatment. Treatment of drug-resistant TB is more complex, more expensive, and has a higher failure rate than that of susceptible TB. Globally, the treatment success rate for multidrug-resistant/rifampin-resistant TB was 59% in 2020. HIV patients are up to 2-4 times more likely to die when treated for MDR-TB, but ART and high-quality TB treatment can reduce mortality. To control the acquisition and transmission of drug-resistant TB in HIV-endemic areas, improved treatment regimens are essential [5].

The diagnosis of drug-resistant tuberculosis (DR-TB) relies on the bacteriological identification of drug-resistant strains, as no clinical or radiological signs are specific for the disease. For this, it is essential to explain to the patient the method of spitting, which should be done during a coughing effort after a deep inspiration, to obtain a quality sample. Salivary sputum is not useful.

Direct microscopy is the most common test used to diagnose tuberculosis because it identifies contagious cases. However, bacilloscopy cannot identify resistant tuberculosis. It is therefore recommended as an adjunct to the Xpert test, which can detect resistance to rifampin, a drug commonly used to treat TB. The Xpert test is an automated diagnostic test that can provide results in less than 2 hours from sputum samples. However, it is not recommended for patient follow-up, as it may reveal the presence of genetic material even after the patient has recovered [6].

Other molecular tests, such as the LPA GenoType MTBDR plus, prevent the identification of genetic mutations that make *M. tuberculosis* strains resistant to certain drugs. The Xpert test is also recommended for extra-pulmonary TB, although it is not suitable for all types of specimens. It is recommended for samples of cerebrospinal fluid, lymph nodes and other tissues. However, its sensitivity is limited for stool or urine samples [7, 8].

It is important to note that the shedding of *M. tuberculosis* is intermittent, so it is recommended that two tests be performed to improve diagnostic sensitivity.

The standard chest radiograph is usually the first imaging test performed when a patient presents with chest symptoms. It is complementary to the clinical evaluation and often provides key information for diagnosis. This imaging method uses x-rays to visualize lung, pleural, mediastinal and spinal lesions. Although standard radiography is the basis for diagnosis of pulmonary tuberculosis, it is insufficient in 30-40% of cases. Computed tomography (CT) is more sensitive for detecting small lesions or areas poorly explored on standard radiography, such as the lung apex, and for assessing signs of disease activity, detecting complications, and guiding specimens. It is also a reference examination to

analyze the extent of sequelae. In addition to nodulo-infiltrative sequelae, it is also important to assess the bronchial tree for bronchial dilatation and to detect the presence of residual lung cavities, the persistence of which most often leads to surgical treatment to prevent superinfection complications, in particular aspergillosis. CT surveillance is not systematic during treatment, but may be performed in some cases. After treatment has been discontinued, CT is useful for assessing sequelae and for searching for residual lung cavities. CT uses contiguous or disjointed slices for optimal study of the parenchyma and can be performed with deep inspiration or supine. Spiral CT is faster and allows a volumetric exploration without the risk of missing some slice levels [9, 10].

Magnetic resonance imaging (MRI) is generally not widely used for the diagnosis of pulmonary abnormalities caused by TB because of its high cost and limited availability. However, when performed, it can show some parenchymal abnormalities such as condensations, excavations, and nodules, with good correlation to CT findings. Micronodules are not well studied on MRI. Tuberculous adenopathies show specific signal abnormalities on T2 sequences depending on their stage of evolution. They may be moderately hypersignal when they are the site of lymphoid hyperplasia due to inflammation. When they are the site of caseous necrosis, they present a central hyposignal surrounded by a hypersignal corona. Their liquefaction results in a frank hypersignal. These 3 stages cannot be distinguished on CT. On the other hand, MRI is the technique of choice to study the consequences of tuberculous pericarditis. Positron emission tomography coupled with CT can also be used to assess lesion activity, extension, locate a biopsy site, and evaluate therapeutic response. PET scans correlate with signs of CT activity and a decrease in PET scans reflects a good response to anti-tuberculosis therapy. Two patterns of uptake have been described: a lung uptake pattern with moderate uptake in nodular and excavated parenchymal lesions and a lymph node uptake pattern. However, the place of 18F-fluorodeoxyglucose (FDG) PET scans in infectious diseases is not clearly validated [10, 11, 13].

The NIX-TB trial is a single-arm, open-label study conducted in South Africa. The study was designed to evaluate the 26-week safety and efficacy of the new BPAL (Bedaquiline, Linezolid and Pretomanid) regimen in patients with extensively drug-resistant or multidrug-resistant tuberculosis who had failed second-line therapy. A total of 109 patients were enrolled, 56 of whom were HIV-positive. Results showed that 90% of patients had good outcomes 6 months after treatment, but toxic side effects of Linezolid were also observed, such as peripheral neuropathy and myelosuppression in 81% and 48% of patients, respectively. The study also determined that toxicity could be reduced without compromising the efficacy of the BPAL regimen by reducing the dose and duration of Linezolid. Although the BPAL regimen has shown a high success rate in treating patients with extensively drug-resistant TB in South Africa, its use is only conditionally recommended because of the

very low-quality evidence underlying the recommendation. More controlled studies are still needed to prove whether BPAL is safer and more effective than other anti-TB regimens. Ongoing clinical trials, such as endTB and TB PRACTECAL, should provide direct, high-quality evidence for short-term, all-oral drug-resistant regimens. [14, 15].

Prevention remains the best way to fight MDR-TB, which involves

- 1) optimal management of each case of tuberculosis from its first manifestation, using effective anti-tuberculosis drugs and avoiding errors in treatment management, such as the trial conducted by a Korean team, which consists of giving an electronic box that opens at a specific time to patients to remind them of the time of taking the treatment with a pre-established pillbox and which helped to have a better compliance, and it is also necessary to have a strong doctor-patient relationship. TB drug resistance surveillance programs are also essential to assess the prevalence of multidrug resistance and guide prevention and treatment strategies. In addition, the development of new drugs and treatment approaches for drug-resistant TB is critical to improving treatment outcomes and reducing the spread of the disease. [16].
- 2) Vaccination: The BCG vaccine is derived from *Mycobacterium bovis* and protects against severe forms of tuberculosis in children. For 10 to 15 years after vaccination, it protects at least 50% of cases of all forms of TB. However, it only protects the vaccinated individual and does not affect the chain of transmission of the disease. In Morocco, where tuberculosis is widespread, BCG vaccination is routinely given to all newborns unless contraindicated. Tuberculin testing of children prior to BCG vaccination is not recommended. Vaccination should be given as soon as possible after birth. However, persons with congenital or acquired cellular immune deficiency, children born to HIV-positive mothers, and persons allergic to any component of the vaccine should not be vaccinated. Vaccine complications include local and regional complications, as well as rare but serious systemic complications. If complications occur, surgery or anti-tuberculosis chemotherapy may be required [17].

6. Conclusion

Since the 1990s, the incidence of drug-resistant or multidrug-resistant tuberculosis has been increasing, especially in developing countries, and is closely correlated with HIV infection. Thus, it constitutes a serious threat to global public health. MDR-TB is associated with a high mortality rate and requires prolonged, complex and expensive treatment, with serious side effects.

Addition, the development of new drugs and treatment approaches for drug-resistant TB is crucial to improve treatment outcomes and reduce the spread of the disease. [18].

References

- [1] Amanda McIvor, Hendrik Koornhof, Bavesh Davandra Kana elapse, *re-infection and mixed infections in tuberculosis disease* Pathog Dis 2017 Apr 1; 75 (3).
- [2] Increased TB cases and deaths during COVID-19 pandemic 27 October 2022 Press release WHO WEBSITE.
- [3] Kargarpour Kamakoli M., Sadegh H. R., Farmanfarmaei G., Masoumi M., Fateh A., Javadi G., et al.. (2017). *Evaluation of the impact of polyclonal infection and heteroresistance on treatment of tuberculosis patients*. Sci. Rep. 7, 41410.
- [4] Barry R Bloom, Rifat Atun, Ted Cohen, Christopher Dye, Hamish Fraser, Gabriela B Gomez, Gwen Knight, Megan Murray, Edward Nardell, Eric Rubin, Joshua Salomon, Anna Vassall, Grigory Volchenkov, Richard White, Douglas Wilson, Prashant Yadav King K Holmes, Stefano Bertozzi, Barry R Bloom, Prabhat Jha. *Tuberculosis Major Infectious Diseases*. 3rd edition. Washington (DC): The International Bank for Reconstruction and Development / The World Bank; 2017 Nov 3.
- [5] Alberto Piubello, auteur principal avec des contributions de Nadia Ait-Khaled José A. Caminero Chen-Yuan Chiang Riitta A. Dlodlo Paula I. Fujiwara Einar Heldal Kobto G. Koura Ignacio Monedero Alberto Roggi Valérie Schwoebel Bassirou Souleymane Arnaud Trébucq Armand Van Deun. *GUIDE PRATIQUE POUR LA PRISE EN CHARGE DE LA TUBERCULOSE RÉSISTANTE*.
- [6] Acuna-Villaorduna C, Vassall A, Henostroza G, Seas C, Guerra H, others. 2008. "Cost-Effectiveness Analysis of Introduction of Rapid, Alternative Methods to Identify Multidrug-Resistant Tuberculosis in Middle-Income Countries." *Clinical Infectious Diseases* 47 (4): 487–95.
- [7] L. Arrivé, L. Monnier-Cholley, Tomodensitométrie du thorax. *Encycl Méd Chir, Pneumologie*, 6-000-D620, 1998, 14p. 30. Henri Nahum, *Traité d'imagerie médicale*, tome 1, médecine-science, Flammarion 2004.
- [8] S. Chaouir, M. Mahi, S. Semlali, J. EL Fenni, *Apport de la tomodensitométrie dans la tuberculose thoracique chez 68 patients immunocompétents, poster électronique, Journées Françaises de Radiologie*. 2005.
- [9] B. Zteou, F. Ghadouani, N. Sqalli Houssaini, S. Tizniti, MC. Benjelluon, M. EL Biaze, B. Amara, H. Mahla, *la tuberculose thoracique dans sa forme typique et atypique, poster électronique, Journées Françaises de Radiologie* 2007.
- [10] MF. Carette, M. Azencot, C. Le breton, F. Breittmayer, J. M. Bigot, *Aspect radiologique actuel de la tuberculose thoracique, Société Française de Radiologie et d'Imagerie Médicale, Cours d'enseignement post-universitaire (EPU), Novembre 1992*.
- [11] panelB. Kouassi a, A. N'Gom a, K. Horo a, C. Godé a, B. Ahui a, N. M. L. Emvoudou a, N. Koffi a, J. C. Anon a, K. F. Konaté a, M. Itchi a, M. O. Koffi a, A. Ano a, S. F. Manewa a, A. Gro Bi a, E. Aka-Danguy a, A. Gnazé b, K. Touré *Revue des Maladies Respiratoires Volume 30, Issue 7, September 2013, Pages 549-554 Correlation of the manifestations of tuberculosis and the degree of immunosuppression in patients with HIV*.
- [12] S. Hantous-Zannad, A. Zidi, H. Néji, M. Attia, I. Baccouche, K. Ben Miled-M'rad *Apport de l'imagerie dans la tuberculose thoracique*.
- [13] Qiaoli Yang, BS, a Jinjin Han, MS, a Jingjing Shen, MS, b Xinsen Peng, MS, c Lurong Zhou, BS, *et Xuejing Yin, Médecine (Baltimore). 2 septembre 2022 *Diagnostic et traitement de la tuberculose chez les adultes vivant avec le VIH*.
- [14] Francesca Conradie, M. B., B. Ch., Andreas H. Diacon, M. D., Nosipho Ngubane, M. B., B. Ch., Pauline Howell, M. B., B. Ch., Daniel Everitt, M. D., Angela M. Crook, Ph.D., Carl M. Mendel, M. D., Erica Egizi, M. P. H., Joanna Moreira, B.Sc., Juliano Timm, Ph.D., Timothy D. McHugh, Ph. D., Genevieve H. Wills, M.Sc., et al., *Treatment of Highly Drug-Resistant Pulmonary Tuberculosis for the Nix-TB Trial Team**.
- [15] N. Benfenatki Service de médecine interne, établissement public hospitalier, La Revue de médecine interne, 2009, Alger, Algérie Disponible sur Internet le 22 octobre 2009, *La Tuberculose multirésistante*.
- [16] Pr M. Bouskraoui (CHU - MOHAMMED VI MARRAKECH) Dr Y. Piro (DELM) Direction de l'Epidémiologie et de Lutte contre les Maladies Programme National de Lutte Antituberculeuse Algorithmes et procédures opérationnelles standards Prise en charge de la tuberculose chez l'enfant, l'adolescent et l'adulte.
- [17] A El Kamel, S Joobeur, N Skiri, Cheikh Mhamed, H. Mribah, N Rouatbi: Lutte contre la tuberculose dans le monde *Revue Pneumologie Clinique*. 2015 avril-juin; 71 (2-3): 181-7. Publication en ligne du 28 mai 2014.
- [18] Christoph Lange, Dumitru Chesov, Jan Heyckendorf, Chi C Leung, Zarir Udwadia, Keertan Dheda *Respirology* 2018 Jul; 23 (7): 656-673. Drug-resistant tuberculosis: An update on disease burden, diagnosis and treatment.