



Case Report

Isolated Thrombocytopenia as an Initial Presentation of Systemic Lupus Erythematosus: A Case Report of a 17 Year Old Female

Rizwanullah^{1,*}, Shehriyar¹, Khayam², Muhammad Saad¹, Aiysha Gul³

¹Department of Medicine, Hayatabad Medical Complex, Peshawar, Pakistan

²Department of Medicine, Combined Military Hospital, Peshawar, Pakistan

³Department of Gynaecology and Obstetrics, Hayatabad Medical Complex, Peshawar, Pakistan

Email address:

urizwan600@gmail.com (Rizwanullah), shehriyarkhan541@gmail.com (Shehriyar), khayam756@gmail.com (Khayam), msaad113117@gmail.com (Muhammad Saad), Ayesha0342@gmail.com (Aiysha Gul)

*Corresponding author

To cite this article:

Rizwanullah, Shehriyar, Khayam, Muhammad Saad, Aiysha Gul. Isolated Thrombocytopenia as an Initial Presentation of Systemic Lupus Erythematosus: A Case Report of a 17 Year Old Female. *American Journal of Internal Medicine*. Vol. 11, No. 3, 2023, pp. 60-63. doi: 10.11648/j.ajim.20231103.16

Received: May 14, 2023; Accepted: May 27, 2023; Published: June 6, 2023

Abstract: *Background:* Childhood systemic lupus erythematosus (SLE) can manifest in various ways, with hematologic abnormalities being common. However, isolated thrombocytopenia is relatively infrequent. *Case Presentation:* In this case report, we describe a 17-year-old female patient who presented with complaints of generalized body aches, weakness, anorexia, and recent epistaxis, with no relevant medical history, medication use, smoking, or bleeding disorder in the family. After excluding infectious and other autoimmune causes, SLE was the final diagnosis due to high ANA and anti-dsDNA titers. Despite conventional steroid therapy, the patient's platelet count remained low, prompting the increase of prednisolone up to 2mg/kg/day. By day 7th, the platelet numbers reached to 85000/ μ l, indicating a favorable response. *Conclusion:* Our findings suggest that when isolated thrombocytopenia does not respond to conventional steroid therapy, SLE should be considered, and that a child presenting with isolated hematological abnormality should be screened for childhood-onset SLE.

Keywords: Isolated Thrombocytopenia, 17 Years Old Female, Initial Presentation of SLE, ANA, Anti dsDNA, A Case Report

1. Introduction

The occurrence of pediatric SLE is relatively uncommon, new cases that occurring in patients below age of 16 years is 20% [1]. It is possible for immune thrombocytopenia (ITP) to occur before the full-fledged systemic lupus erythematosus by several months or years. The incidence of childhood immune thrombocytopenia (ITP) is 4.3 cases per 100,000 individuals per year. The relationship between ITP and SLE incidence is not yet fully understood. According to Zhu et al., the occurrence of SLE in ITP patients was found to be 4.7%, while the occurrence of SLE in non-ITP patients was 0.19%. This suggests that ITP patients have a 26-fold higher risk of developing SLE compared to the general population [2].

Similar to adults, SLE is more prevalent in females, but as compared to adult, in children female-to-male ratio is lower due to minimal effects of sex hormones [3]. Presentation of SLE in children may vary, but most commonly, initial symptoms include a gradual onset of fever, lethargy, and small joint pain. Hematologic abnormalities such as thrombocytopenia, hemolytic anemia, and leukopenia are also commonly found in children with SLE, but they are typically associated with other specific features of the disease [4]. Nonetheless, isolated thrombocytopenia, as the only manifestation of SLE, is rare. As childhood SLE has few signs and symptoms, early diagnosis and management are critical to avoid serious complications and poor outcomes. In this study, we describe a case of 17years old female presented with

isolated thrombocytopenia, which was later diagnosed as childhood onset SLE.

2. Case Presentation

A 17-year-old female with no previous co-morbidities presented to the emergency department with generalized body aches, anorexia, and weakness for the last month. She had a single episode of epistaxis recently. There was no history of rash, photosensitivity, night sweat, anorexia, hematemesis, hemoptysis, melena, or urinary symptoms. She had no

medication history for the last few months. She was neither a smoker nor had any history of drug abuse. She had no family history of epistaxis or autoimmune diseases.

The patient's vital signs were within normal limits, and there were no visible signs of a rash or restricted movement in her joints. She did not have any small purple spots on her skin or swollen lymph nodes. A thorough examination of her cardiovascular, integumentary, gastrointestinal, musculoskeletal, and neurological systems did not reveal any abnormalities. All baseline investigation shown below (Table 1).

Table 1. Baseline Investigations during hospital stay.

| LAB TEST | UNIT (normal range) | DAY 1 | DAY 3 | DAY 5 | DAY 6 | DAY 7 |
|-----------------------------|---------------------------------------|----------|-------|-------|-------|-------|
| Hemoglobin | g/dl (11.5 – 17.5) | 11.3 | 10.4 | 10.7 | 10.1 | 10.8 |
| Total leukocyte count (TLC) | $\times 10^3/\mu\text{l}$ (4 - 11) | 5.46 | 5.67 | 6.49 | 8.78 | 6.22 |
| Platelet count | $\times 10^3/\mu\text{l}$ (150 – 450) | 7 | 8.9 | 30 | 55 | 85 |
| Retic Count | % 0.5-2.5 | 1.7 | | | | |
| BUN | mg/dl (18 – 45) | 14.8 | | | | |
| Creatinine | mg/dl (0.3 – 0.9) | 0.488 | | | | |
| ALT | IU/l (10 – 50) | 32 | | | | |
| ALP | Mg/dl (35-104) | 47.5 | | | | |
| Serum Bilirubin (SBR) | mg/dl (0.1 – 1.0) | 0.4 | | | | |
| CRP | mg/dl (<0.5) | 1.30 | | 1.34 | | |
| ESR | mm/hr. 0-20 | 35 | | | | |
| RBS | mg/dl (70 - 140) | 72 | | | | |
| SODIUM | mmol/l (135 – 145) | 138.8 | | | | |
| POTASSIUM | mmol/l (3.5 – 5.2) | 3.56 | | | | |
| CHLORIDE | mmol/l (96 - 112) | 106.2 | | | | |
| Dengue NS1 | | Negative | | | | |
| Dengue IgG & IgM | | Negative | | | | |
| Malarial Parasite | | Negative | | | | |
| RA Factor | | Negative | | | | |
| Anti-CCP Antibody | | Negative | | | | |

Complete blood test showed a low platelet count with no abnormal cells present. The patient had elevated levels of CRP and ESR but tested negative for the RA factor and Anti-CCP antibody. Other test results, including retic count, coagulation profile, vitamin B12, and folate levels, were normal. Tests for dengue serology, malaria parasites, and *H. pylori* antigen were negative. Additionally, her 24-hour urinary protein level was within the normal range. After conducting several tests, including an ultrasound of the abdomen and pelvis, a chest X-ray, and an echocardiogram, no abnormalities were found. She was diagnosed as case of immune thrombocytopenia and started her on prednisolone at a dose of 1mg/kg/day. However, after three days, there was no significant improvement in the platelet count, so the dose was increased up to 2mg/kg/day. By day five, the platelet's count had significantly improved to 30,000 μl . Further tests revealed a high titer of homogenous serum ANA at 1: 5120 (normal <1/80) (Figure 1 and Table 2).

Table 2. ANA Profile.

| Test | Result | Titer | Normal Titer |
|--------------------------------|------------|---------|--------------|
| Anti-Nuclear Antibody | Homogenous | 1: 5120 | <1: 80 |
| Anti-mitochondrial Antibody | Negative | | |
| Anti-Smooth Muscle Antibody | Negative | | |
| Anti-Parietal Cells Antibodies | Negative | | |

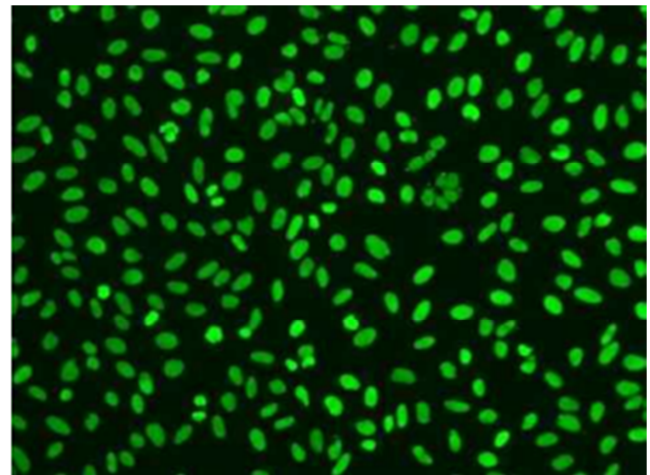


Figure 1. Homogenous ANA (Highly correlated with SLE).

Anti-dsDNA positivity with a level of 412 IU/mL (normal <30 IU/ml) shown below (Table 3) but normal complement levels. The patient's platelet count improved to 85,000 μl by day seven, and she was discharged on oral prednisolone at a dose of 2mg/kg/day. On follow-up after 2weeks patient platelets has been improved with count 140000 μl and sent home on tapering dose with follow up advised. Based on the absence of medication history, the response to high-dose

steroid (cases have been reported), and the high homogenous ANA titer (Figure 1 and table 2) and anti-dsDNA positivity (Table 3), the diagnosis was Systemic Lupus Erythematosus presenting as immune thrombocytopenia without any other organ involvement. May be this patient develop others signs and symptoms of SLE in future.

Table 3. ENA Panel.

| Test | Result | Normal Range |
|-----------------------------|-----------|--------------|
| Anti-RNP | Negative | |
| Anti-Sm | Negative | |
| Ant-SS-A (Ro) | Negative | |
| Anti-SS-B (La) | Negative | |
| Anti-Scl-70 | Negative | |
| Anti-Jo-1 | Negative | |
| Anti-dsDNA | 412 IU/ml | <70IU/ml |
| Anti- Phospholipid Antibody | Negative | |
| Complement 3 | 90 | 70-160mg/dl |
| Complement 4 | 25 | 8-40mg/dl |

3. Discussion

According to research, Chronic ITP develop, in 47% of children with ITP who are 10 years or older. Jung et al. found that in pediatric ITP, 85.9% of cases will go into remission, while 14.1% will become chronic ITP. The age of the child is a prognostic factor for chronic ITP, with older children having a higher risk [5]. Makis et al. also found that age over 10 years is a prognostic factor for developing chronic ITP [6]. The underlying mechanism behind the development of SLE in ITP patients is unclear. ITP can be caused by two primary factors: inadequate platelet production due to a disorder in the maturation of megakaryocytes, or antibody-mediated destruction of platelets that surpasses the compensatory capacity of the bone marrow. In cases where ITP has an autoimmune origin, the immune system perceive glycoproteins on platelet surface (mainly Ib/IX and GPIIb/IIIa) as foreign entity, result into the autoimmune response. The autoantibody's Fc segment binds to Fc gamma receptor (FcγR) on macrophages results in platelets phagocytosis. Studies have revealed that SLE patients with thrombocytopenia have a higher frequency of antiplatelet antibodies than those with no thrombocytopenia. Furthermore, antithrombopoietin receptor antibodies are found more frequently in SLE with associated thrombocytopenia than the ones without a low platelet count [7]. SLE can subsequently develop from ITP in 3-16% cases [8]. Zhao *et al.* reported as ITP can be initial presentation of SLE in 12.8% cases [9]. Hazzan *et al.* During a 4.2-year follow-up study of 222 patients with ITP, it was discovered that 3.6% of them developed SLE. All of the patients who developed SLE were female and had a positive ANA, with a mean age of 12.7 years [10]. Unlike the study conducted by Altintas et al., the development of SLE was not observed in any of the children with positive ANA in their ITP patient group [11]. Diagnosing SLE in children can be challenging due to its heterogeneous presentations. Timely diagnosis and treatment is important to avoid any complication that can impact patient health and life. Two cases of juvenile SLE were

reported by Campos et al. thrombotic thrombocytopenic purpura (TTP) was their initial presentation. These patients also exhibited other specific manifestations of SLE such as neurological and urinary symptoms [12]. A case of childhood onset SLE was described by Sankar Raj, where the patient presented with various symptoms including abnormal choreiform movements, increased temperature, fatigue, weight loss, headache and reduced platelet count [13]. Our study suggests that isolated immune thrombocytopenia, which was unresponsive to recommended doses of steroids, might be an early presentation of SLE. So, ANA and dsDNA tests should be performed in children with isolated idiopathic thrombocytopenia to identify SLE as the underlying disease. The treatment of SLE along with thrombocytopenia is generally similar to that of ITP. The treatment approach for ITP should take into consideration the intricate mechanisms underlying the disease. First line drugs used for treatment include IVIG, Steroid and anti-D immunoglobulin. In cases where first-line treatments fail to control clinical manifestations and thrombocytopenia within 3-6 months, second-line drugs such as thrombopoietin receptor agonists (TPO-RA) and rituximab may be considered. TPO-RA drugs include romiplostim, eltrombopag and avatrombopag. If second-line treatments fail, third-line options are available, including Atorvastatin, azathioprine, cyclosporine A, decitabin (low doses), fostamatinib, hydroxychloroquine, mycophenolate mofetil, oseltamivir, and tacrolimus [14, 15].

4. Conclusion

The occurrence of isolated thrombocytopenia as the sole symptom of childhood SLE is uncommon, and it is advisable to screen children with isolated thrombocytopenia for underlying SLE. If conventional steroid therapy does not produce the desired response in ITP patients, the possibility of secondary ITP should be considered.

Conflicts of Interest

All the authors do not have any possible conflicts of interest.

Author Contributions

All authors contributed equally and they all deserve to be first authors.

References

- [1] Brunner HI, Gladman DD, Ibanez D, Urowitz MD, Silverman ED. Difference in disease features between childhood-onset and adult-onset systemic lupus erythematosus. *Arthritis Rheum* 2008; 58: 556-62.
- [2] Yong M, Schoonen WM, Li L, Kanas G, Coalson J, Mowat F, *et al.* Epidemiology of paediatric immune thrombocytopenia in the general practice research database. *Br J Haematol.* 2010; 149 (6): 855-64. <https://doi.org/10.1111/j.1365-2141.2010.08176.x> PMID: 20377590

- [3] Lahita RG. The role of sex hormones in systemic lupus erythematosus. *Curr Opin Rheumatol* 1999; 11: 352-6.
- [4] McNeil HP, Chesterman CN, Krilis SA. Immunology and clinical importance of antiphospholipid antibodies. *Adv Immunol* 1991; 49: 193-280.
- [5] Sandoval C, Visintainer P, Ozkaynak MF, Tugal O, Jayabose S. Clinical features and treatment outcomes of 79 infants with immune thrombocytopenic purpura. *Pediatr Blood Cancer*. 2004; 42 (1): 109-12. <https://doi.org/10.1002/pbc.10458>, PMID: 14752803.
- [6] Jung JY, Rum OA, MD, Kim JK, Park M. Clinical course and prognostic factors of childhood immune thrombocytopenia: Single center experience of 10 years. *Korean J Pediatr*.
- [7] Audia S, Mahevas M, Samson M, Godeau B, Bonnotte B. Pathogenesis of immune thrombocytopenia. *Autoimmun Rev*. 2017; 16 (6): 620-32. <https://doi.org/10.1016/j.autrev.2017.04.012>, PMID: 28428120.
- [8] Hakim AJ, Machin SJ, Isenberg DA. Autoimmune thrombocytopenia in primary antiphospholipid syndrome and systemic lupus erythematosus: The response to splenectomy. *Semin Arthritis Rheum*. 1998; 28 (1): 20-5. [https://doi.org/10.1016/s0049-0172\(98\)80024-3](https://doi.org/10.1016/s0049-0172(98)80024-3), PMID: 9726332.
- [9] Zhao H, Li S, Yang R. Thrombocytopenia in patients with systemic lupus erythematosus: Significant in the clinical implication and prognosis. *Platelets*. 2010; 21 (5): 380-5. <https://doi.org/10.3109/09537101003735564>, PMID: 20433308.
- [10] Hazzan R, Mukamel M, Yacobovich J, Yaniv I, Tamary H. Risk factors for future development of systemic lupus erythematosus in children with idiopathic thrombocytopenic purpura. *Pediatr Blood Cancer*. 2006; 47 (5): 657-9. <https://doi.org/10.1002/pbc.20970>, PMID: 16933242.
- [11] Altintas A, Ozel A, Okur N, Okur N, Cil T, Pasa S, Ayyildiz O. Prevalence and clinical significance of elevated antinuclear antibody test in children and adult patients with idiopathic thrombocytopenic purpura. *J Thromb Thrombolysis*. 2007 Oct; 24 (2): 163-8. doi: 10.1007/s11239-007-0031-y. Epub 2007 Apr 14. PMID: 17436144.
- [12] Campos LM, Spadoni MS, Michelin CM, Jesus AA, Carneiro JD, da Silva CA. Thrombotic thrombocytopenic purpura at presentation of juvenile systemic lupus erythematosus patients. *Rev Bras Reumatol*. 2013 Feb; 53 (1): 120-6. English, Portuguese. PMID: 23588522.
- [13] Vimal Master Sankar Raj, "An Unusual Presentation of Lupus in a Pediatric Patient", *Case Reports in Pediatrics*, vol. 2013, Article ID 180208, 4 pages, 2013. <https://doi.org/10.1155/2013/180208>
- [14] Dou X, Yang R. Current and emerging treatments for immune thrombocytopenia, *Expert Rev Hematol*. 2019; 12 (9): 723-32. <https://doi.org/10.1080/17474086.2019.1636644>, PMID: 31237783.
- [15] Audia S, Bonnotte B. Emerging Therapies in Immune Thrombocytopenia. *J Clin Med*. 2021 Mar 2; 10 (5): 1004. doi: 10.3390/jcm10051004. PMID: 33801294; PMCID: PMC7958340.